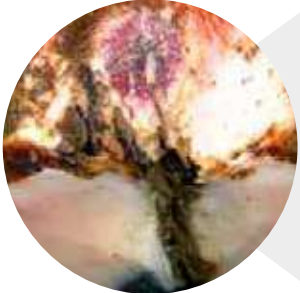







How to prevent and treat hoof conditions



| | Prevention | Treatment | KRUUSE products |
|--|---|--|--|
|  <p>▶ Digital dermatitis</p> <ul style="list-style-type: none"> - Infectious disease of the skin around the hoof - Bacterial agent: Treponema - Highest risk around calving and 1st month of lactation | <ul style="list-style-type: none"> - Good hygiene on floors and in resting areas - Adequately sized eating area - Bi-annual hoof trimming and hoof baths - Disposable boot covers for all visitors - Cleaning boots when moving from one stable section to another | <ul style="list-style-type: none"> - Wash and clean hoof and infected skin area - Use Salicylic acid gel and hoof bandage | <ul style="list-style-type: none"> - KRUUSE Hoof-Gel with Salicylic acid, Cat. No 220402 - KRUUSE BOVIVET Hoof Bandage, Cat. No 220420 - KRUUSE Vet-Flex, Cat. No 160731 - Disposable boot covers, Cat. No 260642 - KRUTEX nitrile examination gloves, Cat. No 261134 - KRUUSE BOVIVET Hoof Dressing, Cat. No 220425 |
|  <p>▶ Interdigital dermatitis</p> <ul style="list-style-type: none"> - Superficial interdigital infection of the skin - Opportunistic bacteria in the environment - Most often on hind limbs | <ul style="list-style-type: none"> - Hygiene - Hoof baths - Dry resting areas | <ul style="list-style-type: none"> - Clean and disinfect hoof and skin - Salicylic acid gel and bandage | <ul style="list-style-type: none"> - KRUUSE Hoof-Gel with Salicylic acid, Cat. No 220402 - KRUUSE BOVIVET Hoof Bandage, Cat. No 220420 - KRUUSE Vet-Flex, Cat. No 160731 - Disposable boot covers, Cat. No 260642 - KRUTEX nitrile examination gloves, Cat. No 261134 - KRUUSE BOVIVET Hoof Dressing, Cat. No 220425 |
|  <p>▶ Heel erosion</p> <ul style="list-style-type: none"> - Degeneration and erosion of the bulb caused by chemicals from the manure - Opportunistic bacteria from the cows environment i.e. Bacterioides Nodosus - Most often hind limbs - More prevalent in older cows | <ul style="list-style-type: none"> - Hygiene - clean and dry walking areas - Hoof baths - Dry resting areas | <ul style="list-style-type: none"> - Clean hoof - Trim all damaged horn - Salicylic acid - Move cow to dry bedding until new horn has hardened | <ul style="list-style-type: none"> - Hoof knives, Cat. No 220052-54 - KRUUSE Hoof-Gel with Salicylic acid, Cat. No 220402 - KRUUSE BOVIVET Hoof Dressing, Cat. No 220425 - KRUUSE Vet-Flex, Cat. No 160731 |
|  <p>▶ Foot rot</p> <ul style="list-style-type: none"> - Acute infectious disease - Fusobacterium Necrophorum and several other bacteria involved - Acute swelling and lameness - Possibly fever and anorexia | <ul style="list-style-type: none"> - Hygiene - Clean and dry walking areas - Dry pastures, especially at entrance areas - Remove sharp objects that can injure the hooves | <ul style="list-style-type: none"> - Systemic antibiotics - NSAIDS - Clean and disinfect hoof and skin - Antibacterial bandage | <ul style="list-style-type: none"> - KRUUSE Hoof-Gel with Salicylic acid, Cat. No 220402 - Cotton polster, Cat. No 160133 - KRUUSE Vet-Flex, Cat. No 160731 - Disposable boot covers, Cat. No 260642 - KRUTEX nitrile examination gloves, Cat. No 261134 |
|  <p>▶ Sole ulcer</p> <ul style="list-style-type: none"> - Ulceration of the sole - Risk of subsequent infection of coffin bone, joints and tendons - Stepping on foreign object - Increased risk in overgrown/untrimmed hooves - Very painful | <ul style="list-style-type: none"> - Bi-annual hoof trimming - Good nutrition to avoid ruminal acidosis and laminitis which weakens the hoof - Keep walking areas free of stones and other foreign objects - Good pasture maintenance | <ul style="list-style-type: none"> - Remove damaged horn - Clean and disinfect ulcer - Use hoof block on opposite digit to free ulcerated digit from weight bearing - Move to dry area with few cows to minimise stress - NSAIDS in acute phase | <ul style="list-style-type: none"> - Hoof knives, Cat. No 220052-54 - Trimming discs, Cat. No 220064 - KRUUSE Hoof Glue, Cat. No 220600-02 - Hoof blocks/shoes, Cat. No 220490-91 |
|  <p>▶ White line disease</p> <ul style="list-style-type: none"> - Separation of white line in the hoof - Often associated with laminitis and a weakened connection between the hoof capsule and coffin bone - Dirt in damaged white line can lead to abscess - Results in chronic changes to the hoof | <ul style="list-style-type: none"> - Bi-annual hoof trimming - Good nutrition to avoid ruminal acidosis and laminitis which weakens the hoof | <ul style="list-style-type: none"> - Correct metabolic imbalance - Trim hooves - Remove foreign material lodged in the white line - Move the cow to an area with soft bedding | <ul style="list-style-type: none"> - ReCovin Rumen Acidosis Paste, Cat. No 310763 - Hoof knives, Cat. No 220052-54 - Hoof trimming discs, Cat. No 220064 |